



Academy of Veterinary Dental Technicians

Credentials Packet 2019-2021

Class of 2021

Credentials Packet 2019-2021

TABLE OF CONTENTS

AVDT Extraction Position Statement	Page 3
AVDT Hours Requirements	Page 4
Specialty (CE) Training Requirements	Page 5-6
Case Logs – Guidelines and Requirements	Page 7-11
Case Reports – Guidelines, Requirements, and Example	Page 12-27
Dental Radiography Requirement and Equipment List Requirement	Page 28
AVDT Required Reading List	Page 29
Form 1: Waiver, Release, and Indemnity Agreement	Page 30
Form 2: Skills Form	Page 31
Form 3a: Specialty Training Wet Lab Form	Page 32
Form 3b: Specialty Training Lecture Form	Page 33
Form 4: Equipment List	Page 34-36
Form 5: Case Log Cadaver Verification Form	Page 37
Form 6: Dental Radiography Cadaver Use Form	Page 38
Form 7: Mentor/Mentee Contacts and Case Log Verification Form	Page 39
Form 8: Mentee Shadowing Hours Verification Form	Page 40
Form 9: Non-traditional CE Form	Page 41
Canine Dental Chart for Case Logs & Case Reports	Page 42
Feline Dental Chart for Case Logs & Case Reports	Page 43
Credentials Packet Submission Process	Page 44
Credentials Packet Mentee Checklist	Page 45
AVDT Extension Policy	Page 46-47

AVDT Extraction Position Statement

The AVDT does not condone, endorse nor recommend that veterinary technicians, credentialed or not, perform dental extractions. Extraction of teeth is oral surgery and should be performed by a licensed veterinarian, per the AVMA. Several states allow for veterinary technicians to perform extractions, but the wording is often vague, some stating simple extractions only, others simply list extractions as a task that can be performed by a credentialed veterinary technician.

The duties of a veterinary technician during a dental procedure include charting, performing dental cleaning (sub-gingival and supra-gingival) and polishing, intraoral radiographs, performing nerve blocks, assisting with the dental procedures and oral surgery. Diagnosing dental disease, prescribing treatment options and medications, and performing oral surgery are duties for the veterinarian. The veterinary technician may and should assist the veterinarian with these duties, thereby ensuring the patient receives the most thorough and efficient dental care.

A Veterinary Technician Specialist (VTS) in Dentistry is a credentialed technician with a special interest in dentistry and oral surgery. They have extensive knowledge and training in these areas (endodontics, exodontics, orthodontics, prosthodontics, and periodontics), however they are not taught nor licensed to perform oral surgery. They may instruct veterinarians on proper extraction techniques under the direct supervision of a licensed veterinarian.

Always refer to your state's veterinary practice act for the duties that you may perform legally.

Credentials Packet 2019-2021

AVDT Hours Requirements

The mentee must spend at least 3200 hours during the Specialist program practicing veterinary technology. At least 2780 of these hours must be spent within a dental setting. Dentistry hours can be accumulated via any of the following routes:

- ✓ Providing client education such as: how to brush teeth, explaining a disease process, your clinics tx recommendations, etc. (anything related to client dental education)
- ✓ Scheduling/assisting with dental consultations
- ✓ Performing/assisting dental procedures (this includes holding the mouth while the veterinarian is suturing, running anesthesia on dental patients, etc.)
- ✓ Performing INTRA ORAL dental radiographs (skull films do not count)
- ✓ Discharging dental patients and going over homecare instructions
- ✓ Creating client handouts for dental related topics for your clinic
- ✓ Shadowing hours required to complete your case logs
- ✓ Dental related CE hours that you have accumulated during your two year mentorship program
 - If you plan to include your hours obtained while attending a dental related CE, confirmation of these hours can be incorporated in your letter from a supervising veterinarian and office manager (see below).

When you submit your credential packet in January 2021, you will be required to submit **THREE - FOUR** documents along with your packet confirming you have worked a minimum of 3200 hours in veterinary technology, and of those 3200 hours, 2780 hours were spent in the field of veterinary dentistry.

These hours must be accumulated between January 1st, 2019-December 31st, 2020.

1. A letter from a supervising veterinarian who can verify that you've worked 3200 hours in the field of veterinary technology, and that 2780 of those hours were spent in the field of veterinary dentistry
2. A letter from your practice manager who can verify that you've worked 3200 hours in the field of veterinary technology, and that 2780 of those hours were spent in the field of veterinary dentistry.
3. A summary of time worked from a timesheet printed out from your employer proving your required hours of 3200 hours in veterinary technology have been met.
4. The fourth documentation is *only* applicable IF you are including hours while shadowing other veterinary clinics. You must complete and sign Form 8. If this form is not completed and signed by the mentee and supervising veterinary (DAVDC or FAVD), these hours will be null and void.

Note: If you shadow multiple clinics, you must print one form per a clinic*

Any applicant who cannot confirm their hours have been met, or were unable to meet the required hours, will not be allowed to submit their credentials packet in January 2021.

Academy of Veterinary Dental Technicians – Class of 2021

Credentials Packet 2019-2021

Specialty Training

In addition to meeting the general requirements, the mentee must successfully complete wet lab training and attend lectures in advanced dentistry procedures. *Teaching a wet lab or lecture or writing a veterinary dentistry continuing education article does not qualify as CE attendance.*

Training and CE credit is accepted from **credentialed** members of the following organizations:

- Academy of Veterinary Dental Technicians (www.avdt.us); Academy of Veterinary Dentistry (www.avdonline.org); American Veterinary Dental College (AVDC.org); Foundation for Veterinary Dentistry (www.f4vd.com)
- Dental local and regional anesthesia CE obtained from a Diplomate of The American College of Veterinary Anesthesia and Analgesia (ACVAA) or Veterinary Technician Specialist (Anesthesia and Analgesia) will be accepted. Any other CE from any other veterinarian, veterinary technician or veterinary technician specialty will NOT be accepted.

A list of CE meetings can be found at each of the above websites, at the Veterinary Dental Forum website (www.veterinarydentalforum.com), the AVDT website (www.avdt.us) or in the *Journal of Veterinary Dentistry*.

The mentee must complete the "Specialty Training Form" (Forms 3a and 3b) and give proof of attendance for each event you attended to show you have completed both the **26 hours** of wet lab training and attended **18 hours** of advanced dentistry lectures. A photocopy of a document provided by the organization or speaker is proof of attendance. Cancelled checks or other documents will not be accepted as proof of attendance. You **must provide detailed course descriptions** provided by the organization presenting the CE as proof that the continuing education was related to veterinary dental care, and the lab or lectures must fit into one of the categories listed below. ***Participation and attendance at wet labs and lectures must be completed during the two-year Specialist training program between January 2019 and December 31, 2020.***

Wet Labs

The mentee must complete a total of **26 hours of wet labs within each of the following disciplines:**

- Dental Prophylaxis – 6 hours
- Periodontics – 6 hours
- Prosthodontics – 2 hours
- Radiology – 6 hours
- Endodontics – 2 hours
- Dental Local and Regional Anesthesia – 4 hours

Advanced Dental Procedures Lectures

The mentee must attend a total of **18 hours of lectures in advanced dentistry procedures:**

- Endodontics – 3 hours
- Prosthodontics – 3 hours
- Orthodontics – 3 hours
- Oral Surgery – 3 hours
- Oral Pathology – 3 hours
- Advanced Periodontal Therapy – 3 hours

Academy of Veterinary Dental Technicians – Class of 2021

Credentials Packet 2019-2021

**Note:* If you are an international mentee and have limited resources and/or are unsure if CE in your country will be accepted, please contact the credential chair for further assistance.

AVDT approved wet labs and lectures may be available at the following conferences or training centers:

1. National Conference of Veterinary Technician Specialty Academies
2. AnimalDentalTrainingCenter (www.animaldentalcenter.com)
3. Veterinary Dental Forum (www.veterinarydentalforum.com)
4. North American Veterinary Conference (www.navc.com)
5. Western States Veterinary Conference (www.wvc.org)
6. Central States Veterinary Conference (www.thecvc.com)
7. American Veterinary Medical Association (www.avma.org)
8. AmericanAnimalHospital Association (www.aahanet.org)
9. AnimalDentalCareTrainingCenter (www.vetdentalclasses.com)

To receive credit for other courses, a written request to and written approval from the AVDT Credentials Chair is required. All CE obtained at the Veterinary Dental Forum will be accepted if it fits into the categories above.

“Non-Traditional” CE Wet lab & Lecture Hour Option

- A Non-Traditional CE Form must be completed and signed by both the trainer and the mentee. See page 41
- A maximum of 5 wet lab hours may be obtained in a non-traditional setting.
- A maximum of 3 lecture hours may be obtained in a non-traditional setting.

Online CE options

- A maximum of 2 lecture hours may be obtained through an online source.
- Skype and Facetime are not acceptable methods to obtain CE hours.

Credentials Packet 2019-2021

Case Logs

A completed AVDT Case Log Spreadsheet must be submitted at the end of the two-year mentorship with a **minimum of 75 dentistry cases**. The AVDT Case Log Spreadsheet has been provided to you along with your other acceptance packet materials. Cases that were treated *prior* to the applicant's acceptance into the AVDT two-year mentorship cannot be included in the case log. Only include cases seen between January 1, 2019 and December 31, 2020.

- Make sure each entry in your log is complete. If the animal's weight (lbs. or kg.), age, or sex is unknown, enter "unknown" in the signalment box. **If you leave any of this information blank, that case will not be accepted**, (please see the Case Log Guidelines section below for additional details explaining how to properly log your cases).
- You will pick **FIVE** cases from your log and write a detailed case report on each. In your case log spreadsheet, please **highlight** the five cases that were used for your case reports using the color blue as indicated at the top of the case log spreadsheet.
- The mentee will use the current, standard diagnostic and procedural abbreviations, as defined by the AVDC. The AVDC updates these abbreviations on an annual basis and it is the mentee's responsibility to use the current abbreviations listed on the AVDC website (www.AVDC.org).
 - The Credential Committee will alert the mentees of the new abbreviations once they have been posted on the AVDC website. Once the new abbreviations have been posted, it is the mentees responsibility to start using the new abbreviations in their case log. The mentee shall identify the date at which the old abbreviations end and the new abbreviations using the color orange as indicated at the top of the case log spreadsheet.

**Note:* If your clinic commonly uses abbreviations that do not appear on the list, please define these at the beginning of your log in the key box at the top of the spreadsheet.

- **If only 75 cases are submitted, a single unacceptable case could result in your credentials packet being rejected; it is recommended that at minimum you include an additional 1-2+ cases per a category.**
- **Along with your case logs, you will be required to pick, and submit, ONE completed dental chart from each case log category that will demonstrate your ability to accurately and properly chart various cases.**
 - You **WILL NOT** submit a dental chart for all 75+ cases. Please use the generic dental charts provided with your credential packets for each case log.
 - However, a completed dental chart must be available for *all* logged cases but need not be submitted unless requested by the AVDT.

Academy of Veterinary Dental Technicians – Class of 2021

Credentials Packet 2019-2021

MINIMUM REQUIRED CASELOAD

- The AVDT prefers the mentee see a live-patient-case with the procedures marked (*). However, if that is not possible, proof of CE in this area is required.
 - This must be highlighted in your AVDT Case Log Spreadsheet and indicated on Forms 3a and/or 3b, as appropriate.
- A cadaver may be used in a maximum of two cases from any category marked (**).
 - These cases are left to the discretion of the mentee but must be performed by a Diplomate of the American Veterinary Dental College or a Fellow of the Academy of Veterinary Dentistry (Form 5).
 -

Oral Medicine

OM Cases requiring involved diagnostic tests (e.g. anesthesia and biopsy and/or radiographs, sialography, masticatory muscle EMG, CBCT, or where laboratory tests beyond complete blood count and biochemical profile are used) but which do not include a specific treatment procedure that is included under a treatment code below.....5

Periodontics

PE1 Complete prophylaxis not requiring involved periodontal treatment.....12
PE2 Involved periodontal scaling and root planing to include placement of a perioceutic medication when no PE3 or PE4 procedure is performed.....5
PE3 Simple periodontal surgery (gingivectomy/gingivoplasty, open curettage or flap procedure, except those combined with bone grafting).....3
PE4* Involved periodontal treatment (osseous surgery, increasing attachment height, bone augmentation, gingival grafting, and guided tissue regeneration, periodontal splinting).....1
Note: extraction followed by placement of a bone promoting or substitute material is not a PE4 case.

Endodontics** (all including routine restoration of access openings)

EN1 Mature canal endodontic obturation - nonsurgical.....7
EN2 Vital pulp therapy (partial vital pulpotomy).....2
EN3* Surgical endodontic treatment, apexification, replacement of avulsed or luxated teeth, splinting of tooth with horizontally fractured root with follow up endodontic evaluation.....1

Restorative Dentistry**

RE Restorative procedures (requiring gingival flap exposure, occlusal table cavity preparation, other involved restoration including routine restoration of endodontic access openings)5
Note: Odontoplasty/dentin bonding is NOT considered a RE case

Oral Surgery

OS1 Simple (closed) dental extractions, crown amputations (tooth resorption).....15
OS2 Involved dental extractions (open or closed, requiring tooth sectioning, bone removal or other procedures in addition to elevator and forceps work). A full mouth extraction patient may be logged as one OS2 case.....12
OS3** Mandibular or maxillary fracture fixation (using dental acrylic splint, body of mandible fracture fixation with wire, pins, screws or plate, symphyseal separation fixation).....1
OS4** Involved oral surgical procedures (TMJ condylectomy, repair of existing palatal defects and oronasal fistulas, maxillectomy, mandibulectomy).....1
OS5** Miscellaneous soft tissue oral surgery (resection of traumatic cheek or sublingual granuloma hyperplasia; salivary gland surgery, removal of oral masses not requiring maxillectomy or mandibulectomy, laser surgery for stomatitis, and operculectomy).....1

Academy of Veterinary Dental Technicians – Class of 2021

Credentials Packet 2019-2021

Note: Therapy laser treatments that do not directly treat the oral cavity DOES NOT count as an OS5

Prosthodontics

PR* Crown and/or bridge preparation, impression and cementation (including canine, incisor and carnassial teeth).....1

Orthodontics

OR* Malocclusion treatment plans (including detailed consultation and evaluation of the bite or bite registration), extraction of deciduous teeth or permanent teeth causing malocclusion, management of clinical malocclusion (crown amputation, application of incline plane), and management of clinical malocclusions (use of and active force orthodontic device).....1

Other Species

EX Dental procedures on animals other than dog and cat, (does not include beak trims, does include occlusal leveling in equine patients)2

Miscellaneous Cases

When a case does not appear to fit into any of the AVDT categories, the applicant is to request clarification and guidance from their mentor. When necessary, the Credentials Chair will forward the query to the Board for consideration.

Counting Cases Under Multiple Categories

Each patient that is anesthetized for a dental procedure equals **ONE** case in your logs. You CANNOT log an anesthetized procedure under two categories, even if it can be categorized as so. If the patient is anesthetized later for a follow up procedure and additional treatment is performed, or another dental procedure is performed, it may be used as an additional entry. For example, if a patient comes in for a root canal treatment and crown preparation, that would be one case. When that patient comes back in for the crown cementation, that would be a second case.

Case Logs Guidelines

Your AVDT Case Log Spreadsheet should conform to the guidelines, nomenclature and abbreviations described below. If at any time you are unsure where a case should be logged, please reach out to your mentor for further guidance.

1. Category

Find the category you are assigning this case to, using the case log categories to determine the category.

2. Number

Each case is assigned a number in consecutive order regardless of what category you're listing your case(s) under. For example, if your first case is an OM case, that case will be labeled as 1; if your second case is an OS5 case, that case will be labeled as case 2. You will not list 1, 2, 3, etc. per a category.

**Please see the examples listed in the case log spreadsheet.*

**If an applicant remains in the training program for more than two years, cases in the log that are now more than two years old can no longer be counted. Please see 46-47 for additional details on extensions.*

3. Date

Month, day, and year procedures were performed.

Academy of Veterinary Dental Technicians – Class of 2021

Credentials Packet 2019-2021

4. Patient Name

List the patient's first and last name. If unsure, please list unknown.

5. Signalment

Species, age, breed, weight (kg or pounds are ok), and gender of the patient. If unsure, please list unknown.

6. Diagnosis

List the diagnosis(es) made using the approved AVDC abbreviations. In this box, **ONLY** include diagnosis(es) that are pertinent to the category you're logging said case under. The box labeled "Other Clinical Findings" will be the box used to listed additional diagnosis(es) that *aren't* pertinent to the category said case is being logged under. *The AVDT requires that the Modified Triadan System of tooth identification be used.*

7. Other Clinical Findings

List the diagnosis(es) made using the approved AVDC abbreviations. In this box, **ONLY** include the diagnosis(es) that aren't pertinent to the category you're logging said case under. If your case doesn't have any additional diagnosis(es), it is ok to leave this box blank.

Note: If a treatment is listed for a tooth that isn't listed in your diagnosis box, that case *will* be rejected since the information listed isn't complete.

8. Dental Procedure

List the treatments performed using the approved AVDC abbreviations. List the treatment(s) starting with the treatment(s) associated with the category you're logging said case under; then log the treatment(s) that aren't pertinent to that category. *The AVDT requires that the Modified Triadan System of tooth identification be used.*

Note: If you use any other abbreviations, a key to these abbreviations must be included at the top of your case log spreadsheet where indicated. Failure to do so may result in a rejected case.

9. Anesthesia

List the gas inhalant used. If a gas inhalant isn't used (i.e. an equine patient that received Midazolam), then you must list the general anesthetic protocol (generic drug names only).

***DO NOT** list preanesthetic or local anesthetic drugs given.

10. Nerve Blocks

Please check this box if a nerve block was performed. ***DO NOT** include drug names or location.

11. Radiographs

- This column is checked if radiographs were taken. ***Intra oral radiographs are a very important tool used to diagnosis, treat, and document dentistry cases. The AVDT requires all cases obtained over the two-year mentorship have radiographs taken. You will NOT get points for a case if the diagnosis and/or treatment requires a radiograph, and radiographs were not taken, i.e. stages of periodontal disease, missing teeth, impacted teeth, root fracture, etc.**

Academy of Veterinary Dental Technicians – Class of 2021

Credentials Packet 2019-2021

The Rules to Remember When Logging a Case

All diagnosis(es) and treatments should be listed and separated as described below. Cases that do not conform to these guidelines will result in a rejected case.

- ✓ Diagnosis/treatment codes listed are to be separated by a semi-colon (;)
Example: AT 304; T/FX/CCF 108
- ✓ When multiple teeth are affected by the same diagnosis or treatment, the diagnosis/treatment must be separated by a comma (,) and the teeth listed are to be separated by a comma (,) and placed in parentheses
Example: GR2, PP4 (104, 204); AB, RR (308, 309)
- ✓ When multiple teeth are affected by the same diagnosis, or multiple teeth are treated the same way, the teeth should *always* be listed in order starting with the 100's, 200's, 300's, and lastly the 400's.
Example: T/FX/UCF (104, 204, 304, 404); AB (309, 409)
- ✓ When logging FOCAL gingival enlargement, you must include the approved gingival enlargement AVDC abbreviation PLUS how many "mm" of growth there is for each tooth.
Example: GE6 108; GE10 208
- ✓ When logging generalized gingival enlargement, you must state so by logging it as:
Example: GE (generalized); PP4 107
- ✓ When logging gingival recession, you must include how many "mm" of recession there is for each tooth.
Example: GR5 104; GR7 204
- ✓ When logging canine and feline tooth resorption, you must include the stages and types as defined on the AVDC nomenclature website. List the stage first and then hyphenate (-) type.
Example: TR4a-T2 304; TR3-T1 404
- ✓ The ONLY procedures that require you to list missing teeth in the diagnostic box are stomatitis and mucositis cases. Since it is of the utmost importance to ensure all the teeth (or cheek teeth) have been removed as part of these patient's treatment, these cases are the one exception for when to list missing teeth in your case log spreadsheet.
- ✓ If a treatment is performed, but it isn't the textbook-treatment-of-choice, you may indicate this by writing the treatment that was performed in the treatment box, followed by "ATO" (alternative treatment option) with the treatment option that is the textbook-treatment-of-choice. Additionally, you may also utilize CDT (client declined treatment), and PPD (dvm elects to postpone treatment) if warranted.

Logging Equine/Pocket Pet Procedures:

- All diagnosis(es) and treatment(s) should conform to the same guidelines as those listed above. You will find equine abbreviations listed on the AVDC website.
 - Currently, there aren't specific abbreviations for pocket pets. If a pocket pet has elongated enamel points secondary to poor husbandry, you must state this in the diagnostic box.
- *Note:* If unsure how to log an equine, or pocket pet case, please reach out to your mentor and/or the credential chair for guidance.

Credentials Packet 2019-2021

Case Reports

You are required to submit five case reports as part of your completed credentials packet. Included in this packet is an example of an approved case report submitted by a successful candidate. Case report guidelines are outlined below.

- Each case report will be a total of 10-12 pages in length.
- The body of the case report(s) must be:
 - **Typed, double spaced, and no more than 8-10 pages in length.**
 - **The second-to-last page of the report is designated for the references, required pictures and radiographs.**
**Note:* Pictures AND radiographs are required. However, only the pictures and radiographs associated with the report should be included. Please do not include full mouth radiographs!
 - **The final page will be the dental chart associated with the case report. Please use the generic dental charts provided with your credential packets for all case reports.**
 - **Cases for your reports must appear in your case logs and be highlighted.**
**Note:* Case reports that are not clearly highlighted in your case logs will not receive points.

Case Report Selection

- Select five various cases from your log that will demonstrate your knowledge and experience in the field of veterinary dentistry.
 - Subjects such as a routine prophylaxis, periodontal disease, a surgical extraction, a vital pulp therapy, a root canal treatment, or an oronasal fistula repair, etc. can potentially be great options for case reports!
**Note:* Mentee's are encouraged to write five case reports on five *different* subjects.
- These case reports should describe in detail, how the patient was diagnosed and treated.
 - Pertinent anesthetic information should be included as well.
 - This should include; i.e. route and dose of sedation drugs, induction drugs, maintenance drugs, and any local or regional drugs administered. See specifics under Case Report Guidelines below.
- If you pick a case that is too complicated, it may not represent your knowledge as gracefully as anticipated, and in turn could result in a lower score.
**Note:* "Complications" include anesthesia complications! If a patient is being described as having hypotension, bradycardia, hypothermia, etc., you must include what measures were taken to correct any/all abnormal values. Failure to do so will result in a lower score.
- These case reports **do not** need to be cases that are done at an exotic facility such as a zoo or wildlife sanctuary. Your mentor will be a great resource to help you pick cases that will be successful as case reports.

Academy of Veterinary Dental Technicians – Class of 2021

Credentials Packet 2019-2021

- Be sure that information such as the patient's first and last name, the assigned case log number, and the date the case was seen is included in the report. This information is used to ensure the case is entered in the case log correctly. It is important that the information in your case reports be clearly understood. Present each case in a logical manner, check spelling and grammar, and define any abbreviations.

CASE REPORT GUIDELINES

A case report is an opportunity to show good dental concepts and the ability to deliver a well written and well-documented scientific paper about a case performed by current standards. The use of advanced technology or skill in the case reports are not required. Your mentor and the Credentials Committee will evaluate each of the items below.

- ✓ Read your manuscript while playing the role of a critic.
- ✓ ***Keep it technical. Please remember that this is scientific writing, and spelling and grammar are very important. Plagiarism will result in severe penalties.***
- ✓ Above all, prepare your case reports early enough to seek pre-approval by your mentor, leaving enough time to edit and return it again well before your Credentials Packet deadline.

***Note: Case reports where a technician is doing any surgical treatments, including surgical extractions, will automatically receive zero points regardless of the mentee's state regulations.** Please refer to our AVDT position statement on page 3 and/or contact the current Credential Chair with any additional questions regarding this guideline.

Case Report Title

The title should include the patient's first name, last name, what type of case it is, the case log number, and the date. **Example:**

Katie Burdick
A Periodontal Disease Case
Case Log #122 - 8/16/2012

The Body of the Case Report

1. History

- Include a signalment and the presenting problem or chief complaint.
 - Was the patient referred to your clinic? Why was the patient referred?
- Describe past dental history if relevant.
 - Has your clinic been monitoring a tooth and up until this dental procedure everything was ok?
 - Was an epulis removed during last year's dental procedure and now this year it's back?
 - Does the owner brush the teeth daily and the fractured tooth was noticed at home?
 - Were pre-operative diagnostics and laboratory tests performed by the referring veterinarian?
- Describe past medical history if relevant.
- Describe any other *relevant* problems.

Credentials Packet 2019-2021

2. Awake Oral Exam Findings

- Thoroughly describe the oral exam findings during the consultation.
 - Describe what was seen: gingivitis index, calculus index, obvious mobile teeth, etc.
 - Mention all oral lesions observed.

*Note: You **MUST** refer to teeth in this manner: initially mention the tooth as, “the right maxillary fourth premolar (108),” then subsequently you may refer to the tooth as “108” throughout the rest of the report.

3. Problem List

- Demonstrate attention to the patient as a whole.
 - Mention differential diagnosis and the veterinarian’s rule-outs.
- If applicable, address any potential genetic component of the condition.

4. Treatment Plan

- If applicable, discuss different modalities for treatment and their prognosis.
 - ✓ Why was one “type” of treatment performed over the other?
 - ✓ Was the owner given two different treatment options and they approved treatment option A, over treatment option B?
- If other lesions are apparent, you should mention them and note if they were treated or not.

**Note: Points will be deducted from a case report if additional diagnostics are initially mentioned, but treatment is not included.*

5. Treatment

- Describe the procedure including technique, instruments, and materials used **in detail** using proper terminology.
 - ✓ What was seen during the anesthetized oral exam?
 - Did you chart your findings?
 - ✓ Were intra-oral x-rays taken?
 - ✓ Don’t forget to include the bur numbers and suture(s) that were used in the procedure
 - ✓ If applicable, highlight your involvement in the procedure.
 - ✓ Include post-operative radiographs and their assessment if indicated.
 - ✓ Provide adequate photos to support your report. Provide adequate and accurate captions, labeled pre- operative and post-operative radiographs for procedures and intra operative radiographs for root canal therapy. Again, make sure to label your radiographs and photographs.

**Notes: Do not list equipment manufacturers.*
There is no need to list fine or course prophylaxis paste but if flour pumice is used it should be stated and why.
- **Local anesthetics:**
 - ✓ -What drug was used (generic name)
 - ✓ -What dose in mg per site
 - ✓ -Did you aspirate prior to injecting, and why?
 - ✓ -Did you apply pressure to the injection site once the needle was removed? Why?

Academy of Veterinary Dental Technicians – Class of 2021

Credentials Packet 2019-2021

- **Pre-anesthetic management:**
 - Pre-op vitals should be included.
 - ✓ Heart rate, respiratory rate, initial temperature, etc.
 - ✓ Each vital should include their form of measurement, i.e. BPM, RPM, °F, °C, etc.
 - **Note:* BPM may be used for breaths per minute and beats per minute. If you prefer to state RPM for respirations per a minute and BPM for beats per a minute, that will be accepted too.

- **Appropriate pre-anesthetic and induction protocol including:**
 - ✓ Generic drug name(s)
 - Dose(ages) in milligrams
 - Route of administration
 - ✓ Monitoring observations (if any).
 - ✓ Catheter gauge and location
 - ✓ Did you give the patient flow by O2 prior to induction?
 - ✓ Did you need to run an EKG prior to anesthesia due to a pre-existing condition? Etc.
 - ✓ You MUST indicate what size endotracheal tube was used AND if the endotracheal tube was cuffed or not.

- **Demonstrate appropriate peri-operative monitoring**
 - ✓ What vitals did you monitor and what support was required (if any)?
 - ✓ Intravenous fluid rate/hour. Was an IVF bolus indicated, and why?
 - ✓ How did you control their body temperature
 - ✓ If any abnormalities were observed, you must include them in your report; i.e. an arrhythmia.
 - ✓ Analgesic management is very important. What steps did you take to ensure the pet was comfortable?

- **Detailed post-operative monitoring**
 - ✓ What was your final post-operative vitals?
 - ✓ Was post-operative monitoring required?
 - ✓ Hypothermic? Hyperthermic?
 - ✓ Post-operative pain management?
 - Was the patient on a constant rate infusion pump (CRI)?
 - Why?
 - What drug/dose was used?
 - Include ALL drug names using the generic name, dosages in mg, and route of administration.

- **Discharge instructions**
 - ✓ What medications were sent home (if any)? What are they used for- anti-inflammatory? Pain control? Antibiotics?
 - ✓ Was soft food indicated? For how long? Why?
 - ✓ Can they chew on hard toys? Why or why not?
 - ✓ Recheck appointment? What are you rechecking? What's the importance of rechecking?
 - ✓ Will there be a follow up procedure? i.e. 6-month perio-recheck? 9-month root canal follow-up?
 - What are you rechecking at this follow-up procedure?

Academy of Veterinary Dental Technicians – Class of 2021

Credentials Packet 2019-2021

- What would happen if the root canal failed? Or the tooth that had GTR isn't looking good- now what?
- ✓ Was an annual COHAT recommended for next year?

Discussion

- Discuss any point relative to your case.
- Review the literature on the disease condition and/or procedure in question.
- If applicable, discuss pertinent aspects of the diagnostic work up.

Client Education

- Include all pertinent client education related to your case.
 - ✓ How did you educate the owner about this case?
 - ✓ Are there any preventative measures the owner could take in the future?

Conclusion

- What conclusion, if any, could be drawn from the case?

References

- You must provide references to support your statements. It's recommended that you cite multiple sources.
 - ✓ At minimum, 2 references per case report.
- Format the references as per the American Medical Association (AMA). Specifics about this type of referencing style can be found at: (<http://library.nymc.edu/informatics/amastyle.cfm>)
 - ✓ You must use Arabic superscript numerals OUTSIDE the use of a period and comma *but* INSIDE colons and semicolons*
 - ✓ Number references consecutively in the order in which they are first mentioned in the text.
 - ✓ Author's first and middle name(s) are to be initials only. No periods are needed between initials.
- **Any references listed that ARE NOT on the required reading list, must be included and turned in with your completed credentials packet!!!**
 - ✓ You must include a copy of the cover/copyright page PLUS a copy of the page(s) you're referencing.
*Failure to do so may prolong the grading process of your packet and/or you may be asked by the credential chair to make said copies and turn them in during the grading process.

Academy of Veterinary Dental Technicians – Class of 2021

Credentials Packet 2019-2021

Case report example #1:

Katie Burdick—a periodontal disease case

Case Log #122—8/16/2012

Katie, an 11-year-old, 29.9kg, spayed female Chesapeake Bay Retriever dog, presented for an oral examination due to heavy dental calculus and halitosis. Earlier that week, she had pre-anesthetic laboratory testing consisting of a chemistry panel and a complete blood count; both were within normal limits. Katie was not on any medications and her owner did not provide dental home care. The most recent professional dental cleaning with full mouth radiographs was performed over four years ago. Findings from that procedure included moderate dental calculus (calculus index 2), mild gingivitis (gingivitis index 1), generalized abrasion (AB) on most crown cusps, and a 6mm periodontal pocket between the right maxillary fourth premolar and first molar (108 and 109) that had been treated with closed ultrasonic periodontal debridement and perioceutic application. Radiographically, Katie's teeth looked relatively healthy with less than 25% attachment loss, which was diagnosed as periodontal disease stage 2. At that time, Katie's owner was instructed to return in 6 months for a follow up anesthetized dental cleaning and oral exam to assess the progression of periodontal disease between 108 and 109. However, she had not returned for her recommended re-evaluation later that year.

Conscious physical examination revealed no abnormalities. The patient had an ideal body condition score of 3 out of 5 and was normally hydrated. Her heart rate was 82 bpm, respiratory rate was 18 rpm, and body temperature was 100.3°F. Her conscious oral examination revealed an ideal occlusion, severe generalized dental calculus (calculus index 3), moderate gingivitis (gingivitis index 3), and generalized abrasion on most crown cusps. The level of dental calculus on her teeth made it difficult to evaluate the crowns for discoloration or fractures. She had very obvious halitosis. There were no other abnormalities noted on her conscious oral examination. The owner was presented with a treatment plan, which included; general anesthesia for an oral examination, professional scaling and polishing of the teeth, and full mouth dental radiographs. The owner

Academy of Veterinary Dental Technicians – Class of 2021

Credentials Packet 2019-2021

consented to this treatment plan and asked to be called during the procedure if any additional treatments were indicated.

Katie was administered an intramuscular pre-anesthetic sedative consisting of dexmedetomidine (0.1mg) and butorphanol (6.5mg). The technician also administered a subcutaneous injection of carprofen (65mg) as an analgesic. Once the patient was sedate enough to accept 100% oxygen administered through a mask, the technician placed her in sternal recumbency on a circulating warm water blanket and covered her with an additional warm water blanket to maintain body temperature. The technician then aseptically placed a 22-gauge intravenous catheter in the right cephalic vein and administered a balanced electrolyte solution (150ml/hr, at 5ml/kg/hr) throughout anesthesia to support normal blood pressure. Once the patient was connected to intravenous fluids, the technician drew up propofol at 3mg/kg and administered it slowly via the catheter until the patient was relaxed enough to allow intubation (10mg total). The technician then placed a size 14 cuffed endotracheal tube and connected the patient to a rebreathing anesthetic circuit. The patient's eyes were lubricated with a petrolatum ophthalmic ointment and the technician maintained anesthesia with a mixture of isoflurane (1.75% to 2.0%) and oxygen. Isoflurane concentration was adjusted as needed based on the patient's vital signs and response to stimuli. Anesthetic monitoring included visual assessment, reflex activity, body temperature, oxygen saturation (pulse oximetry), heart rate, respiratory rate, blood pressure, and end-tidal carbon dioxide. The technician monitored these values continuously, and recorded the latter five parameters in the patient's anesthetic log every five minutes.

Once the patient was at a stable plane of anesthesia, the technician rinsed the patient's mouth with a 0.12% chlorhexidine oral rinse to help decrease the amount of aerosolized bacteria during the dental procedure. The technician then took full mouth dental radiographs using a size 2 direct digital sensor plate. All teeth appeared normal radiographically, including the right maxillary quadrant where the patient had been previously treated with ultrasonic periodontal debridement and perioceutic application . Due to the patient's heavy dental calculus,

Academy of Veterinary Dental Technicians – Class of 2021

Credentials Packet 2019-2021

the veterinarian and technician decided to proceed with the dental cleaning before performing a comprehensive oral examination. The technician performed a complete supragingival and subgingival scaling, using a broad-tipped insert for the ultrasonic scaler supragingivally and a periodontal-specific insert on low power subgingivally. While scaling subgingivally, the technician noticed a potentially deep periodontal pocket from the mesiobuccal to the mesiopalatal aspect of the 108. A periodontal probe was used to measure the pocket depth at 9mm, which the technician then recorded on the patient's dental chart and brought to the attention of the veterinarian. Because teeth with periodontal pockets of this depth require either extensive open periodontal surgery or extraction, the technician did not attempt further closed root planing or subgingival scaling of 108.¹ After the technician gently dried all of the teeth using the three-way syringe to check for any chalky-looking calculus deposits left behind, the teeth were polished using a fine-grit prophy paste with an oscillating disposable prophy head. Any leftover paste was rinsed away with distilled water from the three-way syringe.

The veterinarian and technician performed a comprehensive oral examination. The oral cavity was first examined which included the following: extraoral, mandibular lymph nodes, buccal mucosa, tongue, hard and soft palate, tonsils, and pharynx. No abnormalities were discovered on this visual examination. Because the patient's heavy dental calculus had been removed during her scaling and polishing, all surfaces of her teeth were able to be evaluated for abnormalities. As noted on the conscious oral examination, the patient had generalized abrasion (AB) and moderate gingivitis (GI2). Because her gingiva bled when probed, her gingivitis was considered to be moderate instead of mild or marginal.² Other than the 9mm pocket associated with 108, periodontal probing did not reveal any sulcal depths greater than 3mm. There was 2mm of gingival recession associated with the mesiobuccal aspect of 109 and the worn teeth all appeared to have intact tertiary dentin with no pulp exposure. No treatment was indicated for these teeth. The patient's halitosis had improved after the scaling and polishing, but had not entirely disappeared. Halitosis associated with periodontal disease is mainly caused by volatile sulfur compounds that are produced during anaerobic bacterial respiration and tissue destruction.² Based

Academy of Veterinary Dental Technicians – Class of 2021

Credentials Packet 2019-2021

on the oral examination and gingival probing, the veterinarian was able to make a diagnosis of stage 4 periodontal disease. In stage 4 periodontal disease, the attachment loss between tooth root and alveolar bone is greater than 50%, which in dogs can mean periodontal pockets that exceed 7mm.³ Periodontal disease is staged by both attachment loss as well as radiographic changes, although in Katie's case there did not appear to be any radiographic abnormalities associated with her 9mm pocket of 108. Because a radiograph is only a two-dimensional image, it may be difficult to detect vertical bone loss radiographically, especially on an area with significant bony superimposition such as the palatal aspect of a multi-rooted tooth.⁴

After making the diagnosis of stage 4 periodontal disease, the veterinarian called the owner to discuss treatment options. Surgical extraction of the affected tooth, or teeth is frequently warranted for stage 4 periodontal disease. This level of disease can be addressed with aggressive periodontal surgery to debride the tooth roots and promote tissue reattachment, but it still carries a poor prognosis.³ To try and preserve a tooth with stage 4 periodontal disease, annual professional dental cleanings will need to supplement with daily home care. Depending on the patient's individual response, reevaluation and follow-up professional care might be needed as often as every 3-4 months.^{3, 5} After discussion of all of these factors, the owner chose to have 108 surgically extracted rather than try and preserve it with periodontal surgery and daily home care.

At this point, the technician administered an intramuscular injection of morphine (9mg) to the patient and prepared a mayo stand with instruments and supplies for the surgical extraction of 108. A local nerve block of 0.8ml of a 1:4 mixture of 2% lidocaine to 0.5% bupivacaine was injected into the right infraorbital foramen. The technician aspirated prior to injecting the local nerve block to ensure it was not being injected into the patient's bloodstream. The veterinarian used a #15 scalpel blade to gently sever the gingival attachment around 108 to create a full-thickness triangular mucoperiosteal flap. After this, a single vertical releasing incision was made just mesial to the juga of the mesiobuccal root to create a buccal mucoperiosteal flap. Because the maxillary fourth premolars are large, multi-rooted teeth, and two out of the three roots of 108 were still fully surrounded by alveolar

Academy of Veterinary Dental Technicians – Class of 2021

Credentials Packet 2019-2021

bone, nonsurgical extraction was not an option.⁶ The gingival tissues were elevated using a periosteal elevator, and 1/3 of the alveolar buccal bone was removed using a #4 round cutting bur. A #557 crosscut fissure bur was then used to section the tooth into three pieces, each with its own root, and the individual roots were elevated using a luxator and surgical elevators in sizes ranging from 1-4. Once the roots were mobile, they were removed with extraction forceps. Alveoloplasty was performed using a diamond round bur to smooth the alveolar buccal bone in preparation for flap closure. After increasing flap elasticity by incising the periosteum with a #15 scalpel blade, the veterinarian sutured the flap closed with 4-0 chromic gut, in a simple interrupted pattern (Fig. 4). The technician took a post-extraction radiograph to confirm complete removal of all tooth and root structures (Fig. 5). As a final step, the technician applied a waxy polymer plaque preventative paste that will remain on the teeth for 14 days and will reduce the amount of plaque build-up during the initial extraction site healing process.

In preparation for recovering the patient, the technician rinsed the patient's mouth using distilled water from the three-way air-water syringe and checked the oral cavity for any remaining gauze or debris. The technician turned the isoflurane vaporizer off, and the patient was left in lateral recumbency on 100% oxygen for five minutes. The patient's post-operative vitals were normal, except for her temperature which was 97.7°F. She remained connected to all aforementioned anesthetic monitoring equipment until she was extubated. After five minutes on 100% oxygen, the patient was disconnected entirely from the anesthesia machine and recovered until extubation on room air. Once the patient's swallowing reflex returned, the patient was extubated and moved into a recovery cage with a heating unit for continued monitoring. Her temperature was monitored post-operatively until it rose to a more normal body temperature of 100.5°F. She recovered from anesthesia uneventfully, and was bright, alert and responsive and walking on a leash without difficulty at time of discharge. During the discharge appointment, the technician instructed the owner to feed Katie soft food and to avoid hard chew toys and oral play for 10 to 14 days following the surgical extraction to prevent disruption of the sutures. The patient was sent

Academy of Veterinary Dental Technicians – Class of 2021

Credentials Packet 2019-2021

home with carprofen tablets (100mg) PO BID for 5 days and was instructed to give the first oral dose that evening. The patient was scheduled to return for an extraction site recheck 14 days following her procedure.

During the recheck exam in 14 days, once the extraction site is healed, the technician will demonstrate how to provide dental homecare, including proper toothbrush technique and application of the waxy polymer plaque preventative, which should be applied once a week. There are several ways to incorporate a stress-free toothbrush routine. It is a matter of finding the right way for each individual animal and their needs. It is recommended that owner's brush their pet's teeth daily. When first introducing a toothbrush and toothpaste to a pet, it is important to take it one step at a time. The goal is to not struggle and fight with the pet. It should be fun for the pet with positive reinforcement. If the owner is unable to perform daily toothbrushing, it may be recommended that the owner commit to frequent professional, anesthetized dental cleanings to maintain a healthy and comfortable oral status.

It was recommended to Katie's owner to find a Veterinary Oral Health Council (VOHC) approved toothpaste with a palatable flavor. Next, find a schedule that works best for the owner, whether it be every morning, or every night. For the first week, the technician instructed the owner to allow Katie to lick the toothpaste off of her finger, like it's a tasty treat. For the second week, the owner would introduce her finger into Katie's mouth and rub her gums with toothpaste. Once Katie has adapted to her owner's finger rubbing her gums, the owner may introduce a soft bristled toothbrush with toothpaste next. The technician stressed the importance of finding an appropriately sized toothbrush that works best for Katie's" size and to ensure the bristles are not too hard. If the owner brushes the teeth with hard bristles and/or too aggressively, the owner could create pseudopockets, gingival recession, sensitive, bleeding gums. These negative effects of toothbrushing could cause Katie to resist homecare because of the discomfort it's causing. Once Katie and her owner have found a good schedule and Katie is desensitized to the toothbrush, the owner was instructed to focus on brushing the buccal and labial aspects of Katie's teeth, since the palatal and lingual aspects are hard to reach on an awake pet. Starting

Academy of Veterinary Dental Technicians – Class of 2021

Credentials Packet 2019-2021

in the back of her mouth, and moving rostral, the owner should brush 3-5 strokes per quadrant, with the toothbrush directed 45 degrees towards the gingiva to disrupt plaque near the gingival sulcus. Lastly, the technician informed the owner that some areas are harder to reach than others, so not to get discouraged if she is unable to brush the teeth thoroughly. The owner scheduled a 3 month follow up exam with the technician to assess the homecare routine. However, if the owner was having difficulties with homecare prior to the 3 month recheck, the owner was encouraged to come in sooner.

The technician also suggested trying an approved Veterinary Oral Health Council (VOHC) water additive to help control plaque formation. The owner was told that the prognosis for periodontal disease is extremely variable and depends on the patient's own immune response as well as both the professional oral care and home care that the patient receives.² Because of this, the owner was encouraged to schedule Katie for an anesthetized oral examination, dental cleaning, and radiographs in 6 months to monitor potential progression of periodontal disease.

Periodontal disease is the inflammation of the supporting structures of the teeth which is defined as the periodontium. The periodontium consists of the attached gingiva, the periodontal ligament, the cementum, and the alveolar bone. Several studies have shown periodontal disease to be the most commonly diagnosed disease of dogs and cats.³ Although periodontal disease has complex, multi-faceted pathophysiology, it has its beginnings in the bacteria that inhabit the pellicle—the thin layer of glycoproteins deposited on teeth by saliva. As the bacteria count rises, their by-products cause the pellicle to thicken into plaque; this process takes about 24 hours. These bacteria are mostly aerobic and gram-positive.³ As the plaque thickens, it develops subgingivally, where it causes inflammation of the tissues which results in gingivitis. Plaque is soft and sticky and can be removed by toothbrushing. Gingivitis is reversible if plaque is removed. If plaque is not removed, over the next 2-3 days, calcium compounds from the saliva mineralize and harden the plaque—at which point it is termed dental calculus. Calculus cannot be removed by toothbrushing.⁵ As the calculus thickens, it irritates the gingiva, provides a rough

Academy of Veterinary Dental Technicians – Class of 2021

Credentials Packet 2019-2021

surface for more plaque to adhere, and provides an oxygen-poor environment for new species of bacteria to populate. These bacteria are typically anaerobic and gram-negative, and their metabolic by-products create more severe inflammation and tissue destruction of a tooth's supporting structures. At this point, reversible gingivitis has become irreversible periodontitis—the active destruction of periodontal tissues. Only about 25% of bacteria cultured from healthy canine subgingival tissues are anaerobic, but when periodontal disease is present the anaerobes make up as much as 95% of the bacterial population. There is a host component to this process as well. As the patient's immune system tries to destroy the invading bacteria it may end up damaging the periodontal tissues as well. Because different animals will have different immune responses, two dogs with similar plaque burdens may develop widely differing degrees of periodontal disease.³ As periodontal disease progresses, the gingiva detaches and recedes from the alveolar bone which form periodontal pockets; this is where more plaque and anaerobic bacteria develop. Eventually, the periodontal ligament and alveolar bone degenerate and the teeth become mobile which ultimately results in tooth loss.³

Animals with periodontal disease may present with a wide range of signs and symptoms, depending on the severity of their condition. In earlier stages, gingivitis, halitosis and calculus deposition may be the only signs. As periodontal disease worsens, patients may develop gingival recession, root exposure, purulent discharge around teeth, mobile teeth, oral pain, and ulcerated gingiva.^{3,5} Because the disease is often undetected by owners in its early stages, the halitosis associated with advanced periodontal disease is commonly the initiating factor for the visit to the veterinarian, as it was in Katie's case.⁵ The goal in treating periodontal disease is to remove all contributing factors of inflammation from the patient's oral cavity and reestablish healthy periodontal tissues. This is accomplished by removing all supra- and subgingival plaque and calculus from teeth providing periodontal therapy or oral surgery if indicated by the presence of periodontal pockets or gingival recession, and extracting teeth that cannot be preserved with treatment or surgery.³ Following professional dental care, there are many products available for owners to use at home to help combat plaque formation. These include specially formulated

diets and treats, water additives, plaque preventative gels and waxes, oral rinses, and toothbrushes and pastes.² Dedicated home care by the owner will help maintain a healthy periodontium between professional dental cleanings and is an essential component in the long-term preservation of oral health.

Pictures and Intra Oral Radiographs

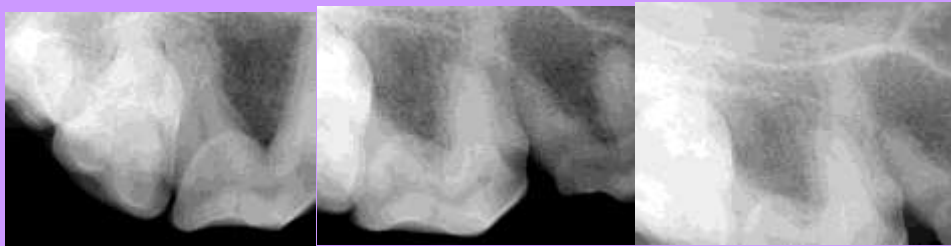

Figure 1: radiographs of 108

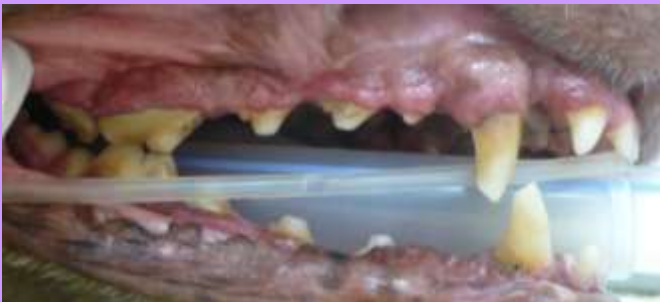

Figure 2: the right maxilla, pre-dental cleaning

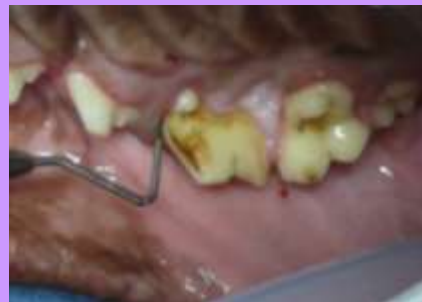

Figure 3: a 9mm periodontal pocket

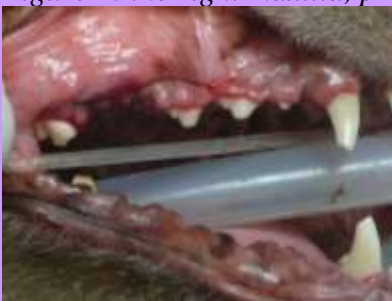

Figure 4: post-extraction and scaling/polishing

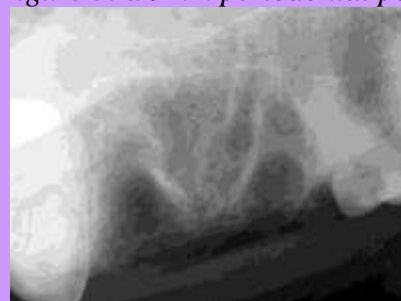

Figure 5: post-extraction radiograph

Academy of Veterinary Dental Technicians – Class of 2021

Credentials Packet 2019-2021

References

1. Holmstrom SE, Frost P, Eisner ER. *Dental Prophylaxis and Periodontal Disease Stages. Veterinary Dental Techniques for the Small Animal Practitioner*. 3rd ed., Philadelphia: Saunders; 2004: 175-232.
2. Lobprise, HB. *Blackwell's Five-Minute Veterinary Consult Clinical Companion—Small Animal Dentistry*. Ames: Blackwell Publishing Professional, 2007; 3-13, 163-165, 172-180.
3. Wiggs RB, Lobprise HB, *Periodontology. Veterinary Dentistry—Principles and Practice*. Philadelphia: Lippincott-Raven; 1997: 186-231.
4. DuPont G, DeBowes L. *Atlas of Dental Radiography in Dogs and Cats*. St. Louis: Saunders; 2009: 134-141.
5. Perrone JR. *Small Animal Dental Procedures for Veterinary Technicians and Nurses*. Ames: Wiley-Blackwell, 2013; 106-115.
6. Holmstrom SE, Frost P, Eisner ER. *Exodontics. Veterinary Dental Techniques for the Small Animal Practitioner*. 3rd ed., Philadelphia: Saunders; 2004: 291-338.

Credentials Packet 2019-2021

"Katie" Burdick 8/16/2012 Case Log #122
Case Report #1

Canine Dental Chart

104 204
9mm PP
404 304

- Generalized AB throughout
- CI 3
- GI 3
- PD 4

PP = periodontal pocket ABBREVIATIONS: X = surgical extraction
GR - gingival recession
CI - calculus index
GI - gingivitis index
PD - periodontal disease

Credentials Packet 2019-2021

Dental Radiography Requirement

The mentee must provide one complete set of **intra-oral** dental radiographs of a dog, and one complete set of **intra-oral** dental radiographs of a cat, to show proficiency in dental radiography. Digital radiographs are required.

The radiographic requirement is fulfilled as follows:

- ✓ A full-mouth series of a live dog and cat or dog and cat cadaver with ***permanent and complete dentition***.
- ✓ Cadaver radiographs are accepted, and they do not need to be intubated (see Form 7).
- ✓ Whole skull radiographs are unacceptable.
- ✓ Radiographs should be mounted and labeled appropriately: identifying client, patient, date, animal age and breed. Labeling requirements are noted in *Veterinary Dental Techniques, 3rd Ed*; (Holmstrom, S.E., Frost P., Eisner E.R., WB Saunders, 2004) and *Small Animal Dental Procedures for Veterinary Technicians and Nurses*; (Perrone, J.R., Wiley-Blackwell, 2013)
- ✓ High quality .jpg images or images imbedded in a Word.doc are required.
- ✓ ***Radiographs must include all roots.***
 - If necessary 2 views may be used to show both the crown and root of larger patients. You must label them as so, i.e. “Apicies of 309,” “Cusps of 309.”

AVDT CHECKLIST FOR SUBMITTING RADIOGRAPHS

- ✓ All adult teeth to be evaluated are clearly visible. ***Radiographs must include complete permanent dentition.***
- ✓ The maxillary teeth should have the crowns facing downward and the roots upwards.
- ✓ The mandibular teeth have the crowns facing upward and the root downwards.
- ✓ When viewing the right side of the mouth, the anterior teeth are on the right side.
- ✓ When viewing the left side of the mouth, the anterior teeth are on the left side of the radiograph.
- ✓ Proper angulation is used.
- ✓ There is no foreshortening or elongation.
- ✓ Adequate visualization crowns and apices—at least 2mm space around each, 2 views are acceptable
- ✓ Exposure/developing technique is adequate.
- ✓ No artifacts are seen on the image.
- ✓ Correct contrast and density of the radiograph.
- ✓ File sheets should be labeled according to AVDC guidelines—radiographs should be mounted and labeled appropriately, identifying client, patient, date, animal age, breed and Triadan number

Equipment List Verification Form

A copy of the equipment list verification form (Form 4) must be completed and signed by the mentee and the mentee’s supervising veterinarian.

**Note: If this form is turned in but not signed, the mentee will not receive any points for section.*

Required READING LIST Class of 2021

1. Heidi B. Lobprise. *Blackwell's Five-Minute Veterinary Consult: Small Animal Dentistry*. Second Edition. Wiley-Blackwell, 2012.
2. Niemiec, B. A., Gawor J., & Jekl V. *Practical Veterinary Dental Radiography*. CRC Press, 2018
3. Niemiec, B., *Veterinary Periodontology*. First Edition. Wiley-Blackwell, 2013.
4. Holmstrom, Steven E. *Veterinary Dentistry: A Team Approach*, Third Edition. Saunders, 2018.
5. Niemiec, Brook A. *Small Animal Dental, Oral & Maxillofacial Disease: A Color Handbook*. Second Edition. Manson Publishing, 2011.
6. Perrone, Jeanne R. *Small Animal Dental Procedures for Veterinary Technicians and Nurses*. Wiley-Blackwell, 2012.

Note: * In the event that a mentee cannot find a required reading book via “regular” online or in-person bookstore retailers, it is recommended that the mentee inquire about said book(s) via “in-state borrowing” and/or “out-of-state borrowing” through their local library and/or university.

Suggested reading list:

1. *Journal of Veterinary Dentistry* (previous 2 years prior to exam): F4VD membership required
2. Dupont, Gregg A. and DeBowes, Linda J. *Atlas of Dental Radiography in Dogs and Cats*. Saunders, 2009.
3. Wiggs, Robert B. and Lobprise, Heidi B. *Veterinary Dentistry Principles & Practice*. Lippincott-Raven, 1997.
Note: The new version of this book is set to be released in March 2019
4. Gail E. Marshall. *Companion-Animal Dental and Surgical Instruments: A Reference for Veterinary Technicians and Assistants*. First Edition. AAHA Press, 2011
5. Bartolomucci, Linda R. *Dental Instruments: A Pocket Guide, 4th Edition*. Saunders, 2011.
6. *Step by Step Compendium*. May be ordered through the Foundation of Veterinary Dentistry: (<http://www.f4vd.com/compendia.html>)
7. Niemiec, B. *Feline Dentistry for the General Practitioner*. May be ordered through: (<https://www.dogbeachvet.com/for-veterinary-professionals/products-bookstore>)
8. Dupont, Gregg A. and DeBowes, Linda J. *Atlas of Dental Radiography in Dogs and Cats*. Saunders, 2009.
9. Kesel, M. Lynne. *Veterinary Dentistry for the Small Animal Technician, First Edition*. Wiley-Blackwell, 2000.
10. Bellows, Jan. *Feline Dentistry: Oral Assessment, Treatment, and Preventative Care*. Wiley-Blackwell, 2010.

*Mentees should also look at other dental handbooks and periodicals available, including technician magazines, which offer special features on dentistry.

Academy of Veterinary Dental Technicians – Class of 2021

Credentials Packet 2019-2021

Form 1

WAIVER, RELEASE, AND INDEMNITY AGREEMENT

I hereby submit my credentials to the Academy of Veterinary Dental Technicians for consideration for examination in accordance with its rules, and enclose the required fee. I agree that prior to, or subsequent to my examination, the Board may investigate my standing as a technician, including my reputation for complying with the standards of ethics of the profession. I understand and agree that the credential fee is nonrefundable.

I agree to abide by the decisions of the Board of Directors of the Academy of Veterinary Dental Technicians and thereby voluntarily release, discharge, and relinquish any and all actions or causes of actions against the Academy of Veterinary Dental Technicians and each and all of its member, directors, officers, examiners and assigns from and against any liability whatsoever in respect of any decisions or acts that they may make in connection with this credentials packet, the grades on such examinations and/or granting or issuance, or failure thereof, of any certificate, except as specifically provided by the Constitution and Bylaws of this organization. I agree to exempt and relieve, defend and indemnify, and hold harmless the Academy of Veterinary Technicians, and each and all of its members, directors, officers and assigns against any and all claims, demands and/or proceedings, including court costs and attorney's fees, brought by or prosecuted for my benefit, extended to all claims of every kind and nature whatsoever whether known or unknown at this time. I further agree that any certificate that may be granted and issued to me shall be and remain the property of the Academy of Veterinary Dental Technicians. Active membership in the AVDT, once accepted, will remain in effect as long as my paid dues are current and I fulfill all recertification requirements.

I certify that all information provided by me in this credentials packet is true and correct. I acknowledge that I have read, understand, and agree to abide by the above two paragraphs.

(Signature)

(Date)

(Please print your name)

Academy of Veterinary Dental Technicians – Class of 2021

Credentials Packet 2019-2021

**Form 2
SKILLS FORM**

Name _____

You are required to state whether or not you have mastered the skills on this form. **Mastery is defined as being able to perform the task safely, with a high degree of success, without being coached or prompted. Mastery requires having performed the task in a wide variety of patients and situations.** The AVDT is aware that some states and provinces may not allow a task to be performed by a credentialed veterinary technician. The AVDT requires that a Diplomate of the American Veterinary Dental College or a VTS(Dentistry) attest to your ability to perform the tasks listed below.

Skill (Applies to both dogs and cats)	Mastered	Diplomate of AVDC or VTS(D) who can attest to mentee's mastery of skill
Identify normal dentition and eruption schedules		
Identify abnormal pathology		
Charting techniques		
Use of hand instruments		
Use of power scaling units		
Subgingival scaling, root planing and curettage		
Taking whole mouth alginate impressions. Experience needed – <i>mastery not required.</i>		
Making stone laboratory models. Experience desired – <i>mastery not required.</i>		
Instrument identification and use sequence in:		
a. Pulpotomy		
b. Pulpectomy		
c. Extractions (non-surgical)		
d. Extractions (surgical)		
e. Periodontal surgery		
f. Oral surgery		
Intraoral Radiology positioning, film processing and mounting		
Maintenance of hand instruments, equipment and dental delivery systems		

Academy of Veterinary Dental Technicians – Class of 2021

Credentials Packet 2019-2021

**Form 3a
SPECIALTY TRAINING FORM
WET LABS**

Name/Applicant Number: _____

SUBJECT	REQUIRED HOURS	HOURS DOCUMENTED	TITLE/SPEAKER/LOCATION/COURSE DESCRIPTION * (highlight if used in case log)
Dental Prophylaxis	6.0		
Periodontics	6.0		
Prosthodontics	2.0		
Radiology	6.0		
Endodontics	2.0		
Regional/Local Anesthesia	4.0		

*More pages may be attached if needed. See page 3, Specialty Training, for required documentation.

Academy of Veterinary Dental Technicians – Class of 2021

Credentials Packet 2019-2021

**Form 3b
SPECIALTY TRAINING FORM
ADVANCED DENTAL PROCEDURES LECTURES**

Name/Applicant Number: _____

SUBJECT	REQUIRED HOURS	HOURS DOCUMENTED	TITLE/SPEAKER/LOCATION/COURSE DESCRIPTION * (highlight if used in case log)
Endodontics	3.0		
Prosthodontics	3.0		
Orthodontics	3.0		
Oral Surgery	3.0		
Oral Pathology	3.0		
Advanced Perio. Therapy	3.0		

*More pages may be attached if needed. See page 3, Specialty Training, for required documentation.

Academy of Veterinary Dental Technicians – Class of 2021

Credentials Packet 2019-2021

**Form 4
AVDT EQUIPMENT LIST**

Name/Applicant Number: _____

Below is the “Required Instruments in Your Practice” and the “Knowledge of Equipment List.” The required section must be initialed by a Supervising Veterinarian, Diplomate of the American Veterinary Dental College or your mentor who can attest that you have those instruments readily available to you in your practice. **Please be aware, all instruments listed below, even the knowledge of equipment, are considered testing materials. Study ALL instruments below!**

Required Instruments In Your Practice	Required	Check if present	Supervising Veterinarian, DAVDC or mentor initials
Safety Glasses/Face Shield	X		
Surgical Mask	X		
Exam Gloves	X		
Ultrasonic or Sonic Scaler with Tips	X		
Hand Scaler(s): Check those that are present at your clinic: <input type="checkbox"/> Sickle Scaler <input type="checkbox"/> Other: _____ <input type="checkbox"/> Jacquette Scaler <input type="checkbox"/> Morse Scaler <input type="checkbox"/> Nebraska Scaler	X		
Hand Curette(s): Check those that are present at your clinic: <input type="checkbox"/> Barnhart <input type="checkbox"/> Other: _____ <input type="checkbox"/> Columbia <input type="checkbox"/> McCall <input type="checkbox"/> Gracey	X		
Periodontal Probe/explorer	X		
Dental mirror			
Compressed Air System with high speed, low speed and 3 way syringe	X		
Handpiece cleaning, conditioning spray or lubricating oil	X		
Prophy Angle	X		
Prophy Cup/paste	X		
Perioceutic Medication	X		
Bone Graft Material	X		
Periosteal elevator	X		
Winged, straight, and/or luxating oral surgical elevators	X		
Extraction forceps	X		

Academy of Veterinary Dental Technicians – Class of 2021

Credentials Packet 2019-2021

Bone Curette	X		
Oral surgery suturing instruments	X		
Root tip forceps and /or pick (these are different!)	X		
Chlorhexidine Oral Rinse	X		
High Speed Cutting burs	X		
High Speed Finishing burs	X		
Dental X-ray Unit	X		
Digital CR and/or DR system and software	X		
Arkansas Sharpening Stone, Arkansas Conical Stone and Honing Oil	X		
Knowledge Of Equipment	Required	Knowle dge of	Check if present
Electrosurgical Unit		X	
Chairside Developer		X	
Automatic Developer		X	
Film Clips		X	
Size 0 Film		X	
Size 2 Film		X	
Size 4 Film		X	
View Box		X	
Endodontic Equipment	Required	Knowle dge of	Check if present
Endodontic File Organizer		X	
Endodontic File Stops		X	
Endodontic Ruler		X	
College-tipped pliers		X	
Paper Points		X	
Endodontic Broaches		X	
Endodontic Files & Reamers: -H-files -K-files -Reamers		X	
File Sterilizer		X	
Gates Glidden		X	
Peeso Reamers		X	
Finger Plugger		X	
Finger Spreader		X	
Electronically Heated Spreader		X	
Irrigation Needles		X	
Irrigation Solution		X	
Chelating Agent		X	
Gutta-percha Heater		X	
Gutta-percha Points		X	

Academy of Veterinary Dental Technicians – Class of 2021

Credentials Packet 2019-2021

Calcium Hydroxide Powder/Cement		X	
ZOE or Other Sealant/Cement		X	
Spiral Paste Fillers		X	
Flour Pumice		X	
Bonding composite resin(s)		X	
Calcium Hydroxide Powder/Cement		X	
Restorative Equipment	Required	Knowle dge of	Check if present
Beavertail/plastic filling instrument		X	
Shofu discs		X	
Mandrel		X	
Light Cure Gun		X	
Dental Chisel		X	
Dental Hatchet		X	
Excavator		X	
Amalgamator		X	
Amalgam Condenser (Plugger)		X	
Amalgam Carver		X	
Mixing Spatula		X	
Mixing Pads		X	
Dentinal Bonding Agent(s)		X	
Glass Ionomer Products		X	
Orthodontics	Required	Knowle dge of	Check if present
Impression Trays		X	
Rubber Mixing Bowl		X	
Mixing Spatula		X	
Vibrator		X	
Model Trimmer		X	
Alginate and/or putty		X	
Polyvinyl siloxane impression material		X	
Articulator		X	
Orthodontic Wire		X	
Orthodontic Buttons		X	
Orthodontic Chain		X	
Articulating paper		X	
Bite wax		X	
Dental Acrylic		X	
Surgical Wire		X	
Dental Pliers		X	
Dental Wire cutters		X	

Academy of Veterinary Dental Technicians – Class of 2021

Credentials Packet 2019-2021

Form 5
Case Log Cadaver Verification Form

I, _____, hereby certify that a dog and/or cat cadaver was used to satisfy my case log requirements in lieu of a live patient. *A cadaver may be used in a maximum of two cases from any category marked (**). These cases are left to the discretion of the mentee, but must be performed and/or supervised by a Diplomate of the American Veterinary Dental College or a Fellow of the Academy of Veterinary Dentistry (Form 5).*

Category	Number	Date	Dental Procedure	Verified by: (signature of DAVDC or FAVD)

Mentee Signature Date

Mentee Name

Mentor Signature Date

Mentor Name

***Form is only required if a cadaver was used to satisfy case log requirements.**

Academy of Veterinary Dental Technicians – Class of 2021

Credentials Packet 2019-2021

Form 6*

Dental Radiography – Cadaver Use

I, _____, hereby certify that a cadaver dog and/or cat cadaver was used in my dental radiography requirement in lieu of a live patient.

Mentee Signature

Date

Mentee Name

Mentor Signature

Date

Mentor Name

***Form is only required if a cadaver is used to satisfy radiography requirement.**

Academy of Veterinary Dental Technicians – Class of 2021

Credentials Packet 2019-2021

Form 7

MENTOR/MENTEE CONTACTS and CASE LOG/CE VERIFICATION

The mentor and mentee met on the following dates via the following form of communication:

Date	Mentee Initials	Mentor Initials	Method of Communication (i.e.: in person, email, phone, etc.)	Nature of Meeting – Topic(s) Covered

Mentee Signature

Mentor Signature±

Mentee Name

Mentor Name

± By signing this form, the Mentor is verifying regular contact with the Mentee, as well as verifying having reviewed the Mentee’s Credentials Packet (including all logs) and CE documentation.

Academy of Veterinary Dental Technicians – Class of 2021

Credentials Packet 2019-2021

**Form 8
Mentee Shadowing Hours Verification Form**

The mentee must complete this form if they'd like their shadowing hours to count towards their total hours at the end of their two year mentorship. The mentee AND supervising veterinarian (DAVDC or FAVD) at the clinic to which these hours were accumulated at must sign this form. If a signature is not present when the mentee turns in this form these hours will be null and void.

Date	Clinic name	Shadowing hours obtained

Mentee Signature

Verified by: (signature of DAVDC or FAVD)±

Mentee Name

DAVDC or FAVD Name

±By signing this form, the supervising veterinarian (DAVDC or FAVD) is verifying the mentee obtained shadowing hours at their clinic.

***** IF you've obtained shadowing hours at multiple clinics, please make copies of this form- do not have multiple clinics on one form. *****

Academy of Veterinary Dental Technicians – Class of 2021

Credentials Packet 2019-2021

Form 9
Non-Traditional CE Form
(fill in the blank)

Continuing Education Title

Continuing Education Description

Continuing Education Date


Mentee Name

Trainer's Name

Mentee Signature

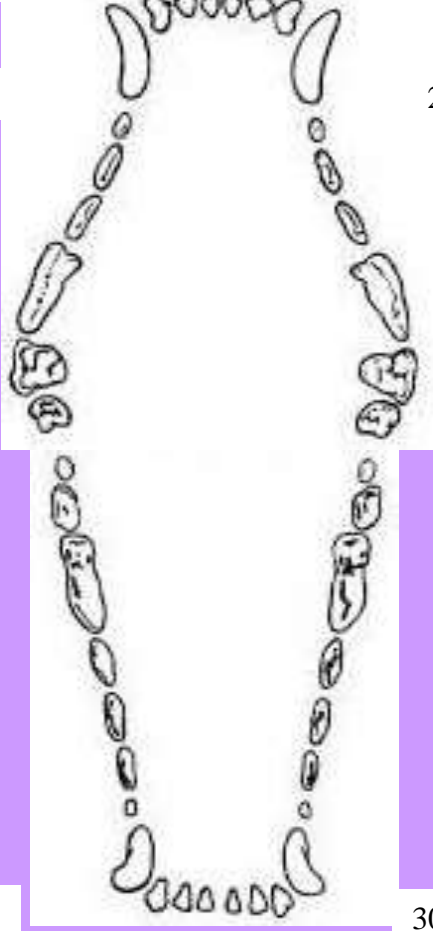Trainer's Signature

Canine Dental Chart



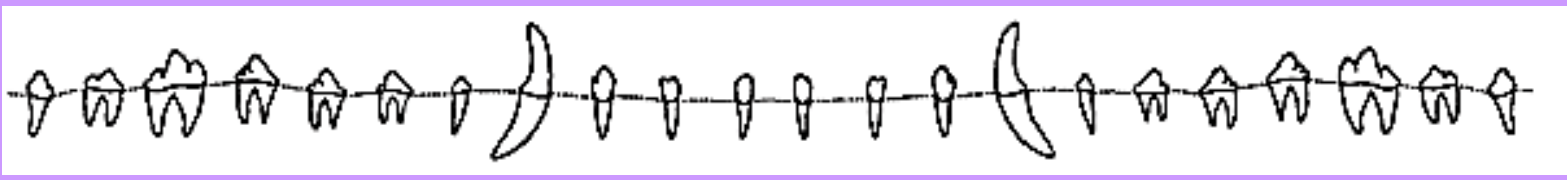
104

204



404

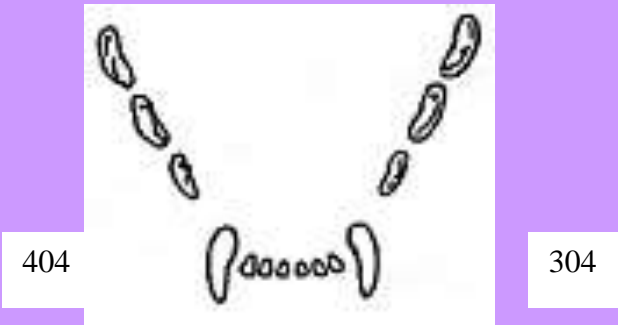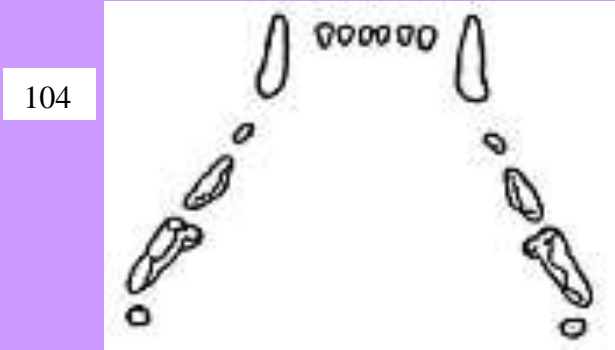

304



ABBREVIATIONS:

Blank area for abbreviations.

Feline Dental Chart



ABBREVIATIONS:

CREDENTIAL PACKET SUBMISSION PROCESS

At the end of the two-year credentialing period, the AVDT Credentials Chair will send each candidate a submission letter. In this letter, you will have specific instructions on how to submit your completed credentials packet by the deadline of January 31st, 2021. Along with these instructions, you will also find your assigned anonymous candidate number. This number will be used to submit an anonymous version of your credentials packet for review to the Credentials Committee. It's imperative that the AVDT keep anonymity during the grading process, so it will be important for you to ensure your name is not on any documents that will be submitted in your anonymous folder. Each candidate will submit TWO versions of their packet in *two* separate folders: one master folder, and one anonymous folder. The master folder will only be seen by the AVDT Credential Chair, and the anonymous folder will be sent out for review to two Credential Committee members.

If you choose to duplicate any form using a word processing program, use the same size and style of font, and the same number of pages. **It is required that you keep a back-up copy of your credentials packet in case of technology failure and for your own reference.** All information included in the original packet should be included in your back-up folder. No packets will be returned to you at the end of the review process. All packets will be destroyed after review.

The credentials packet must be received on or before **January 31, 2021**. Packets received after this date will not be considered for the 2021 exam. **Please keep the Credentials Chair and your mentor up to date on your email address, as this will be used as our primary source of communication.**

Your final score will be an average of the two scores. A perfect score is 100. If an applicant receives 95 – 100 points they will automatically become a candidate for the exam. An applicant receiving 85 – 94 points will be given **two weeks** to correct any needed changes to their credentials packet. Any applicant receiving less than 85 points will be asked to resubmit their packet after an additional year in the program.

Those applicants who are asked to resubmit in January 2022, will need to reacquire everything that they obtained from their first year of credentialing. For the Class of 2021, this will be all material obtained from the year 2019. This does include all case logs, case reports, continuing education, and any x-ray sets obtained in 2019.

Academy of Veterinary Dental Technicians – Class of 2021

Credentials Packet 2019-2021

Mentor/Mentee Checklist

Master Folder Only (all forms below must also be in the Master Folder with original signatures):

Form 1: Waiver, Release, and Indemnity Agreement

Signed by Mentee

Form 7: Mentor/Mentee Contacts and Case Log Verification Form

Signed by Mentor and Mentee

Form 4: Equipment List

Signed by Mentee and Supervising veterinarian

AVDT Program Hours Documentations:

- a. A letter from a supervising veterinarian who can attest that 75% of your time was spent in dentistry & confirming your total hours of 2780.
- b. A letter from your practice manager who can attest that 75% of your time was spent in dentistry & confirming your total hours of 2780.
- c. A summary of time worked from a timesheet printed out from your employer proving your required hours have been met
- d. The fourth documentation is only applicable IF you are including hours while shadowing. You must complete and sign **Form 8**. If this form is not completed and signed by the mentee and supervising veterinary (DAVDC or FAVD), these hours will be null and void.

Blank Dental Records (Canine and Feline) from the clinic the candidate works at

Letter of Recommendation from supervising veterinarian

Anonymous Folder:

Form 2: Skills Form

Signed by supervising DVM

Form 3a: Specialty Training Wet Lab Form

Form 3b: Specialty Training Lecture Form

Proof of CE Attendance- all required CE certificates must be scanned in and sent in with packet

Form 5: Case Log Cadaver Verification Form (if applicable)

Signed by Mentor, Mentee, and supervising DAVDC or FAVD

Form 6: Dental Radiograph Cadaver Form (if applicable)

Signed by Mentor and Mentee

Form 9: Non-Traditional CE Form (if applicable)

Signed by presenter (DAVDC, FAVD, or VTS-Dentistry) and Mentee

AVDT Case Log Spreadsheet

Five Case Reports

Plated Dental Radiograph Sets (Canine and Feline)

Academy of Veterinary Dental Technicians – Class of 2021

Credentials Packet 2019-2021

AVDT Extension Policy

The AVDT understands unforeseen circumstances can occur while a mentee is credentialing. A maximum of two extensions may be granted to each candidate over the course of the mentee's two-year credentialing period. The mentee must submit a formal written request and said request must be approved by the AVDT Credentials Chair to be valid.

The AVDT offers two types of extensions (see below). Both extension types will impact the mentee's credentialing process differently; so it is important for the mentee to understand how both types of extensions work prior to submitting an extension request.

Upon an extension approval, the AVDT Credentials Chair will email the mentee with any/all important documents that may be necessary to continue-on through the credentialing process. Credentialing packets can vary from class to class and a mentee should not assume the same material is in the "new" class that the mentee has been moved into.

If an unusual circumstance arises that does not fit into either category, the Credential Chair may require guidance from the AVDT Executive Board. Board decisions are made through an anonymity process and are considered on a case-by-case basis.

Extension Type I (Non-FMLA)

- Requirements:
 - ✓ An unforeseen circumstance that does not fall into the FMLA category.
- Documentation needed:
 - ✓ A formal written request must be submitted to the Credentials Chair via email
- Following an extension approval, how will this impact the mentee?
 - ✓ The mentee will be moved "back" one year- i.e. moving from the Class of 2018 to the Class of 2019.
 - ✓ All materials collected within the mentee's first year of credentialing will be null and void. This DOES include everything including: credentialing hours, case logs, case reports, continuing education, etc., i.e. if you moved from the Class of 2018 to the Class of 2019, all materials obtained in 2016 (when said mentee started) will need to be acquired again.
 - ✓ The mentee will now reference and study from the materials listed in the "new" credentials packet.
 - *Do not reference the original packet any longer*
 - Any material that has changed, such as the required reading list, case report formatting/referencing, minimum number of cases, hours, etc. will need to be updated to the "new" credentials packet guidelines.

Extension Type II (FMLA)

- Requirements:
 - ✓ An unforeseen circumstance that falls into the FMLA category (medical issues, death in the family, etc.).
- Documentation needed:
 - ✓ A formal written request with proof of FMLA must be submitted to the Credentials Chair via email

Academy of Veterinary Dental Technicians – Class of 2021

Credentials Packet 2019-2021

- Following an extension approval, how will this impact the mentee?
 - ✓ The mentee will be moved “back” one year- i.e. moving from the Class of 2018 to the Class of 2019.
 - ✓ The mentee will NOT lose their first credentialing material obtained over their first year; but instead, the mentee will be required to obtain additional material as outlined below.
 - ✓ The mentee will now reference and study from the materials listed in the “new” credentials packet.
 - *Do not reference the original packet any longer*
 - Any material that has changed, such as the required reading list, case report formatting/referencing, minimum number of cases, hours, etc. will need to be updated to the “new” credentials packet guidelines.

FMLA COMPARISON TABLE

Credentialing Hours	2-year Requirement	FMLA (3rd yr) Requirement
Veterinary Technology Hours	3200	4800
Dentistry Hours	2780	4170
Lecture CE Category	2-year Requirement	FMLA (3rd yr) Requirement
Endodontics	3	4
Prosthodontics	2	3
Orthodontics	3	4
Oral Surgery	3	4
Oral Pathology	3	4
Advance Periodontal Therapy	3	4
Wet Lab CE Category	2-year Requirement	FMLA (3rd yr) Requirement
Dental Prophylaxis	6	7
Periodontics	6	7
Prosthodontics	2	2
Radiology	6	8
Endodontics	2	2
Dental Local and Regional Nerve Blocks	4	4